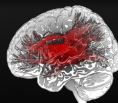


# Etude de la connectomique cérébrale Lors de la régulation émotionnelle, de l'écoute musicale et de la méditation

*Pr. Denis DUCREUX*  
*MD, PhD, HDR*

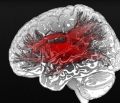


**BRAINANALYZE**

To Analyze the Brain in Function



# IRM Cérébrale Morphologique

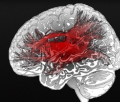
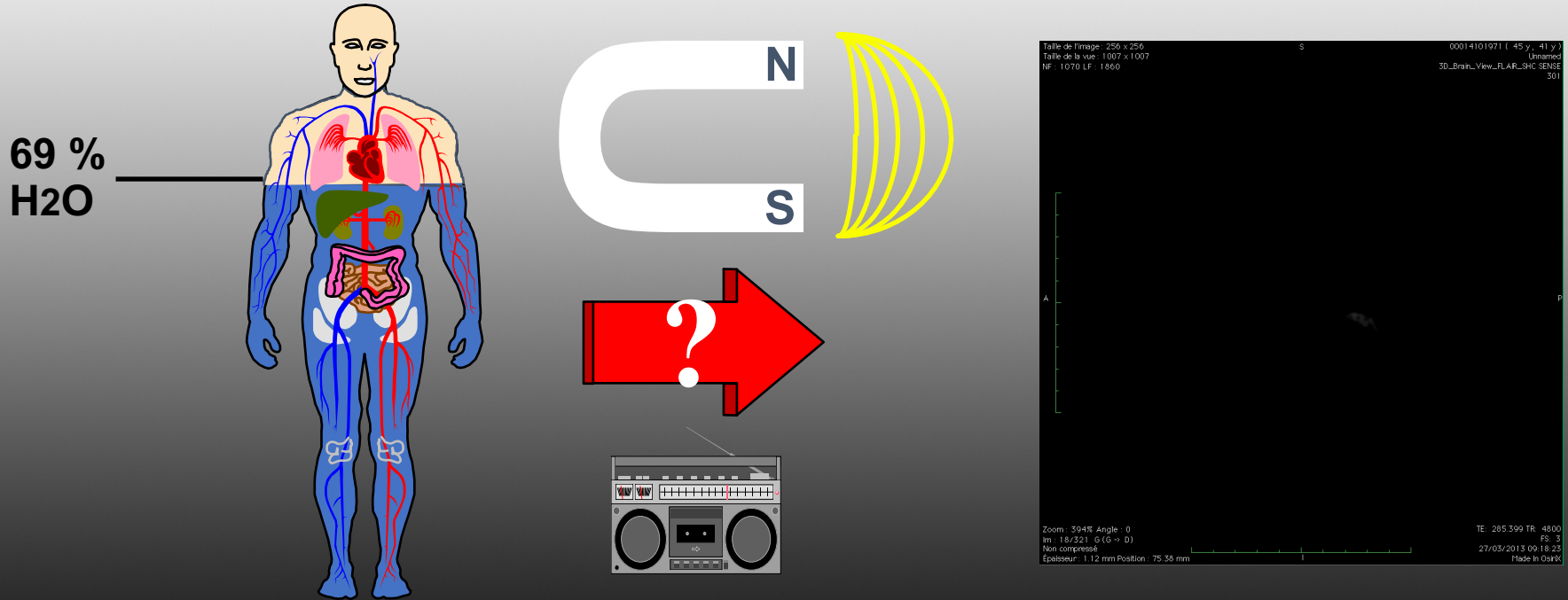


**BRAINANALYZE**

To Analyze the Brain in Function



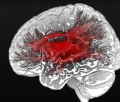
# Principes de l'IRM



**BRAINANALYZE**

To Analyze the Brain in Function

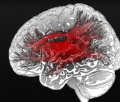
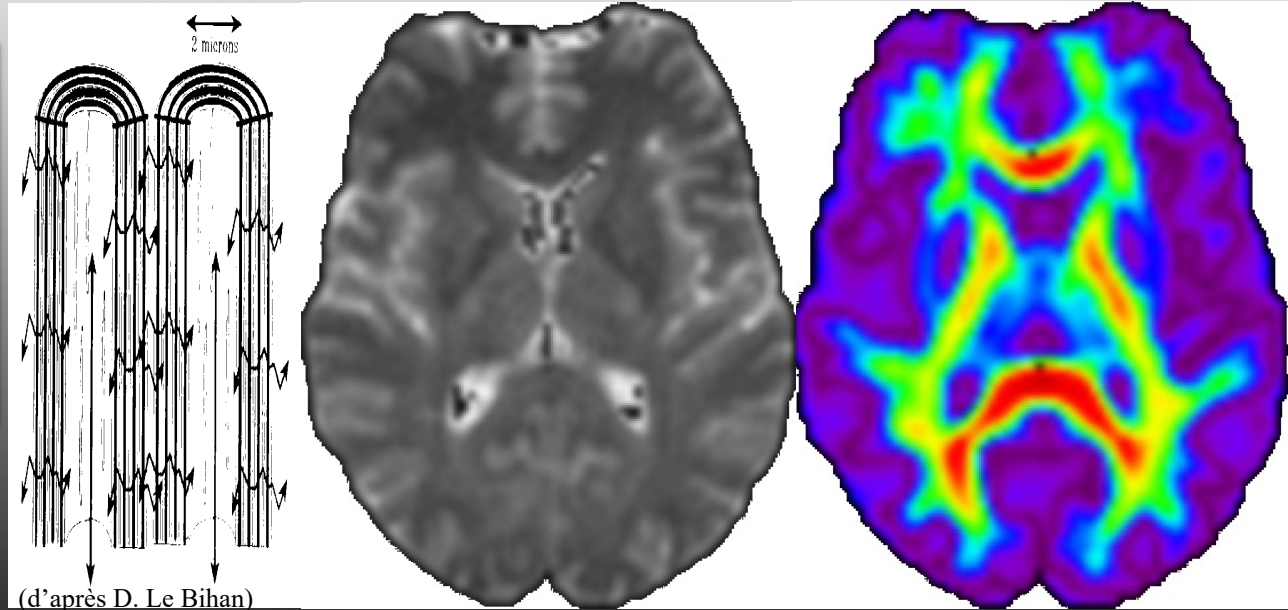
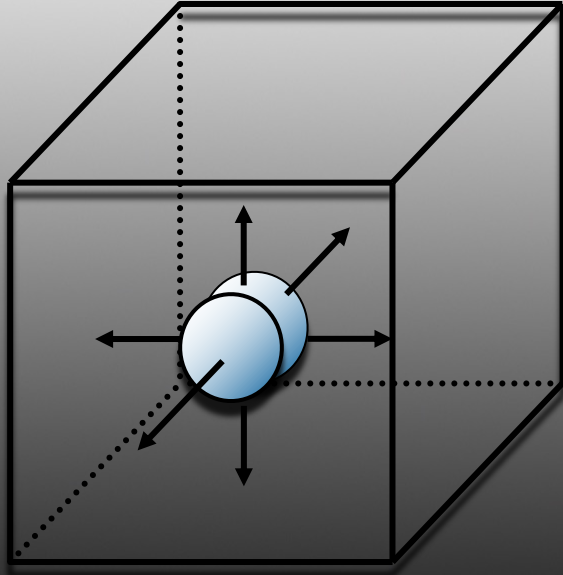
# IRM de Tenseur de Diffusion



**BRAINANALYZE**

To Analyze the Brain in Function

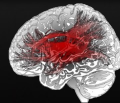
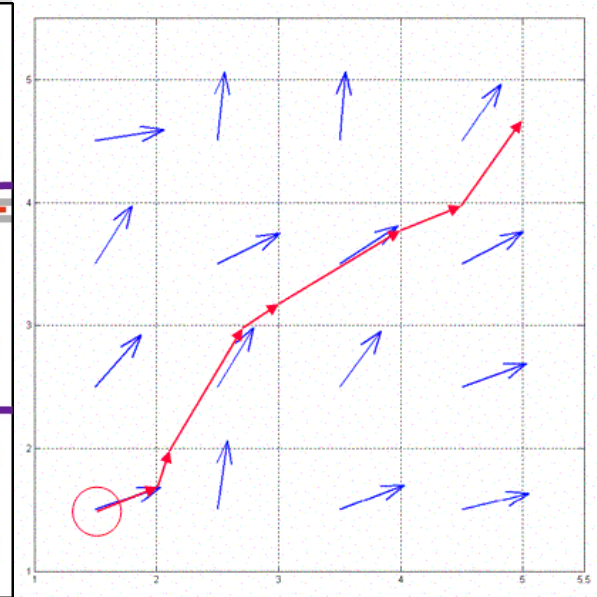
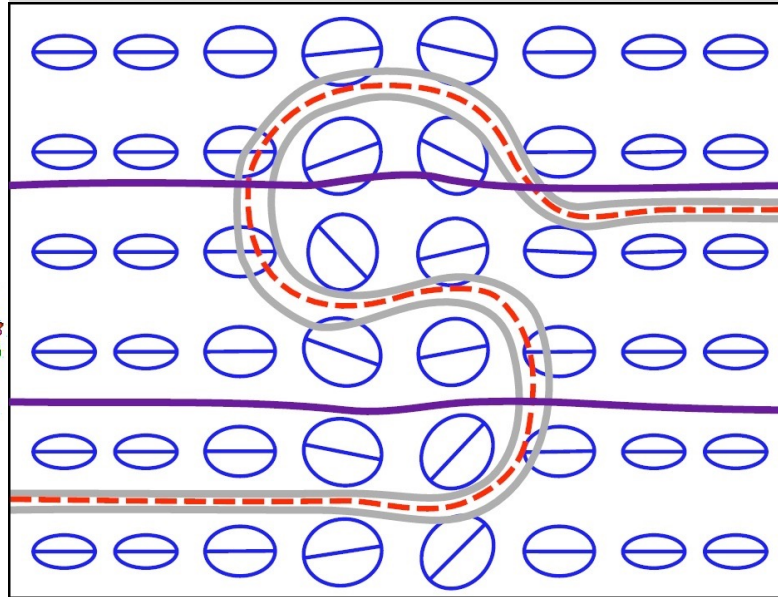
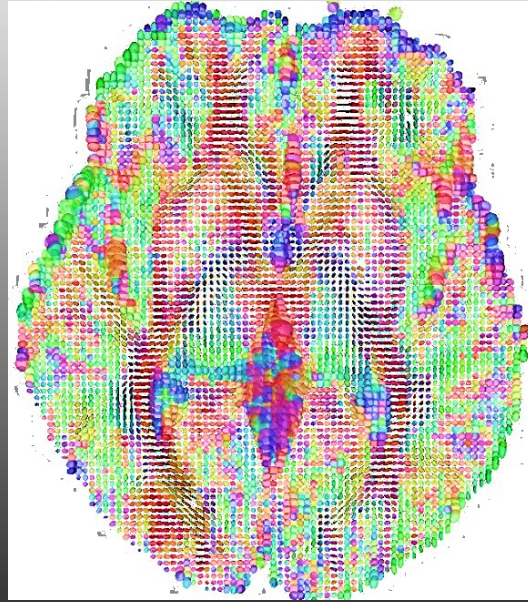
# Principes du Tenseur de Diffusion



**BRAINANALYZE**

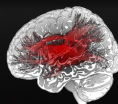
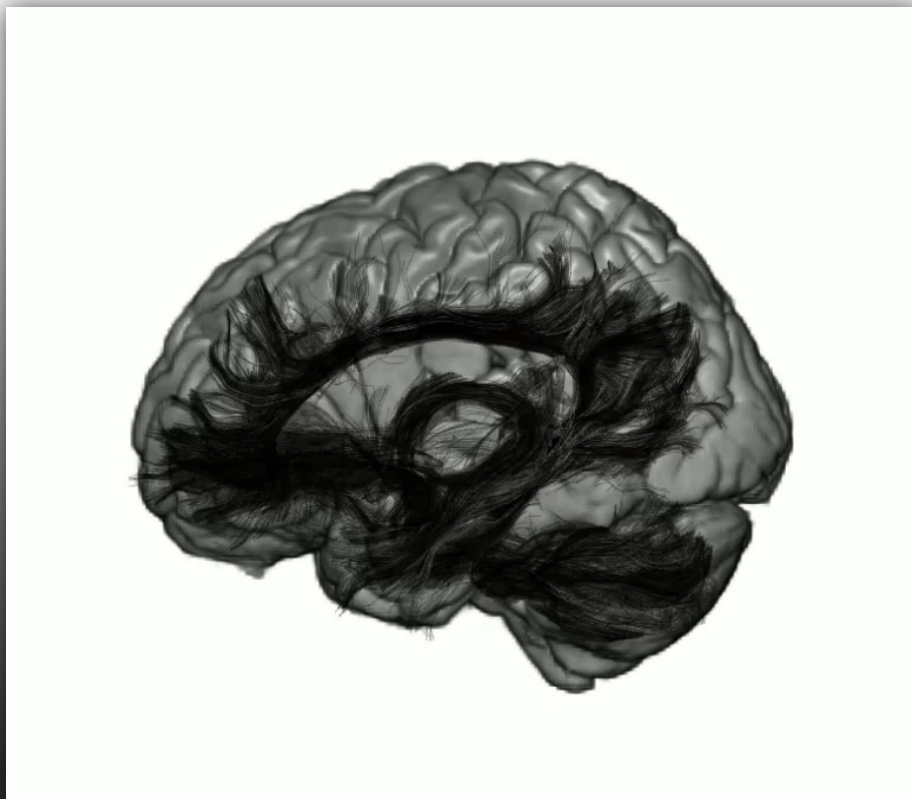
To Analyze the Brain in Function

# Tractographie



**BRAINANALYZE**

To Analyze the Brain in Function



**BRAINANALYZE**

To Analyze the Brain in Function

BrainAnalyze, 25 rue du Maréchal Foch, 78000 Versailles, France



+33 1 39511522



contact@brainanalyze.com



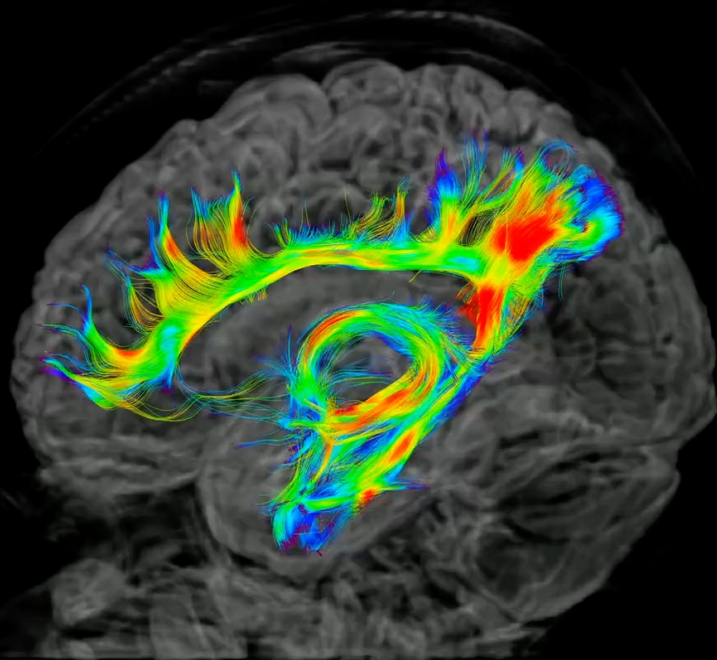
<https://brainanalyze.com>



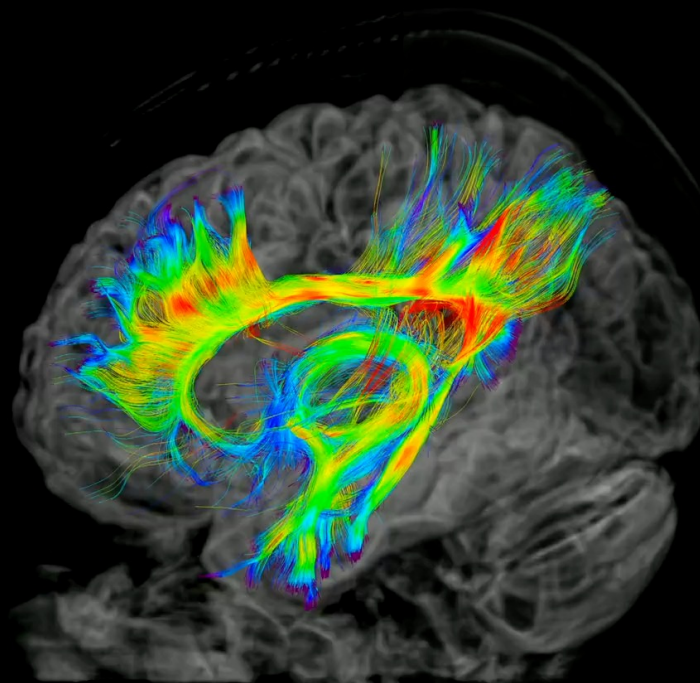
@BrainAnalyze



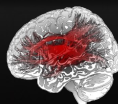
Made with BrainAnalyst



Mild Brain Injury



Normal Subject

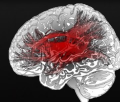


**BRAINANALYZE**

To Analyze the Brain in Function



# IRM Fonctionnelle

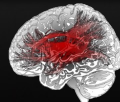
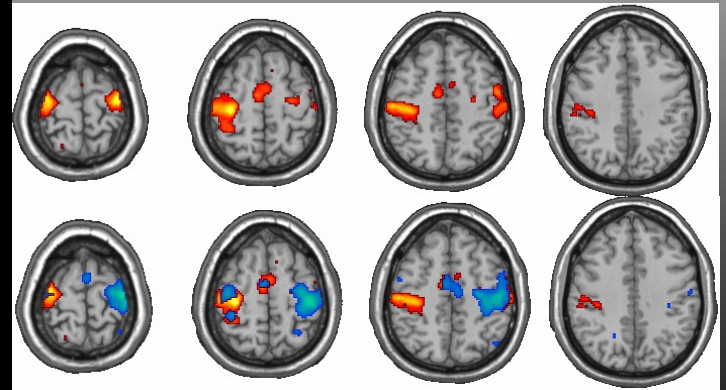
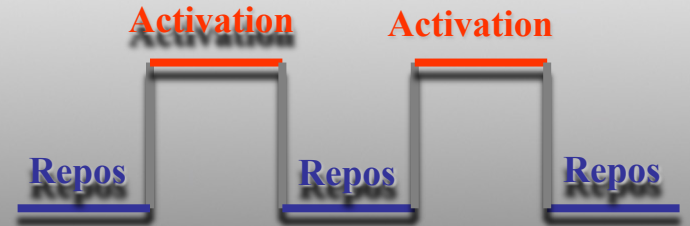
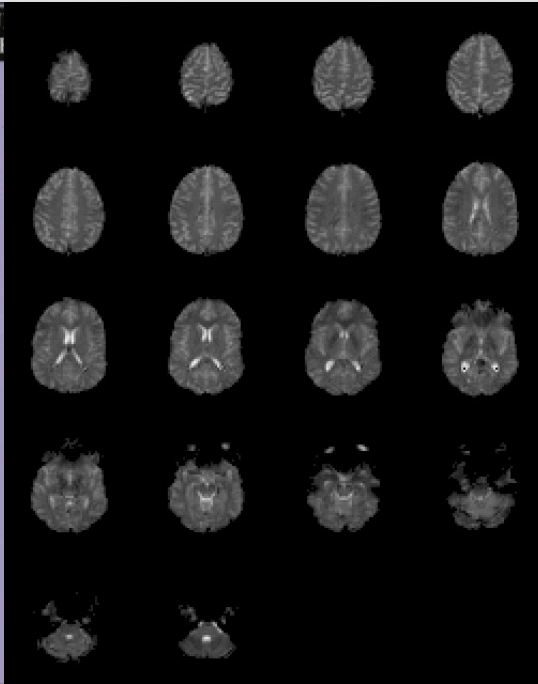
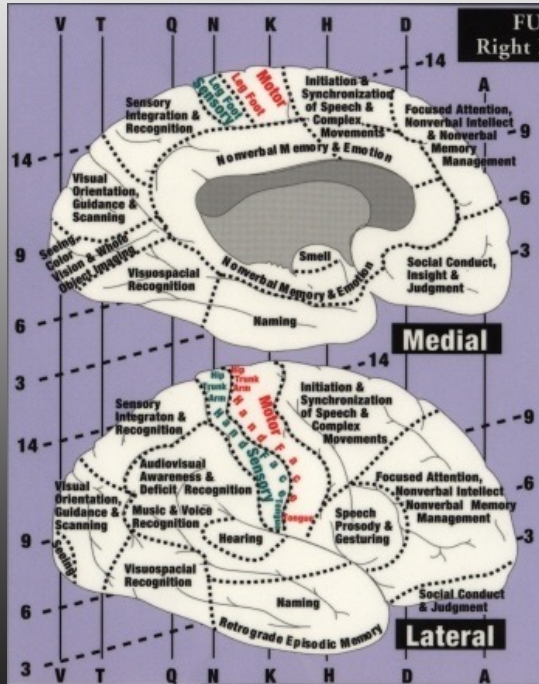


**BRAINANALYZE**

To Analyze the Brain in Function

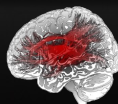
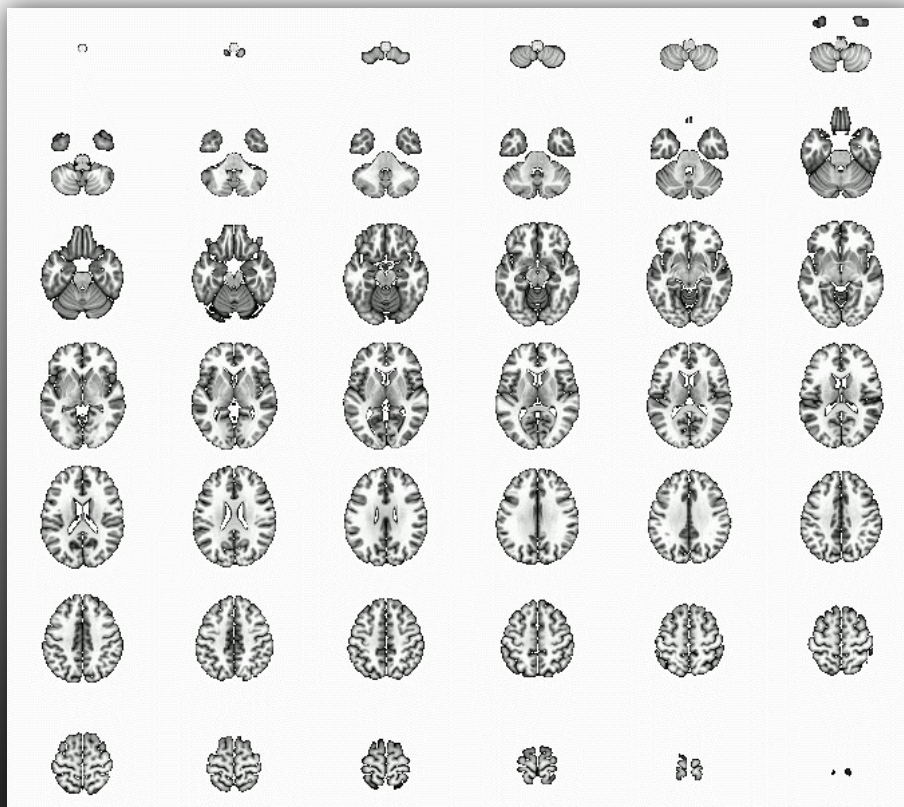


# IRMf : Principes



**BRAINANALYZE**

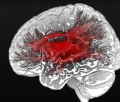
To Analyze the Brain in Function



**BRAINANALYZE**

To Analyze the Brain in Function

# Connectomique

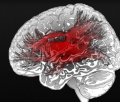
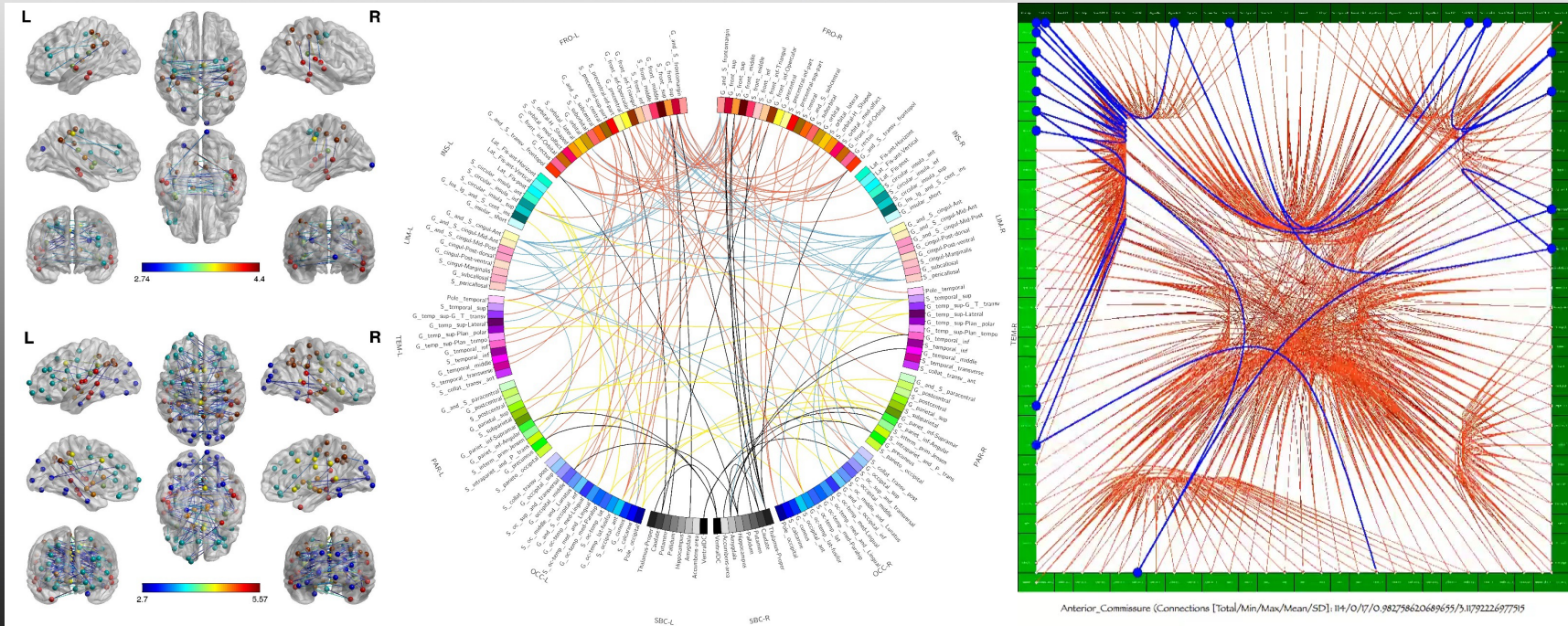


**BRAINANALYZE**

To Analyze the Brain in Function



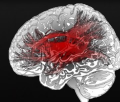
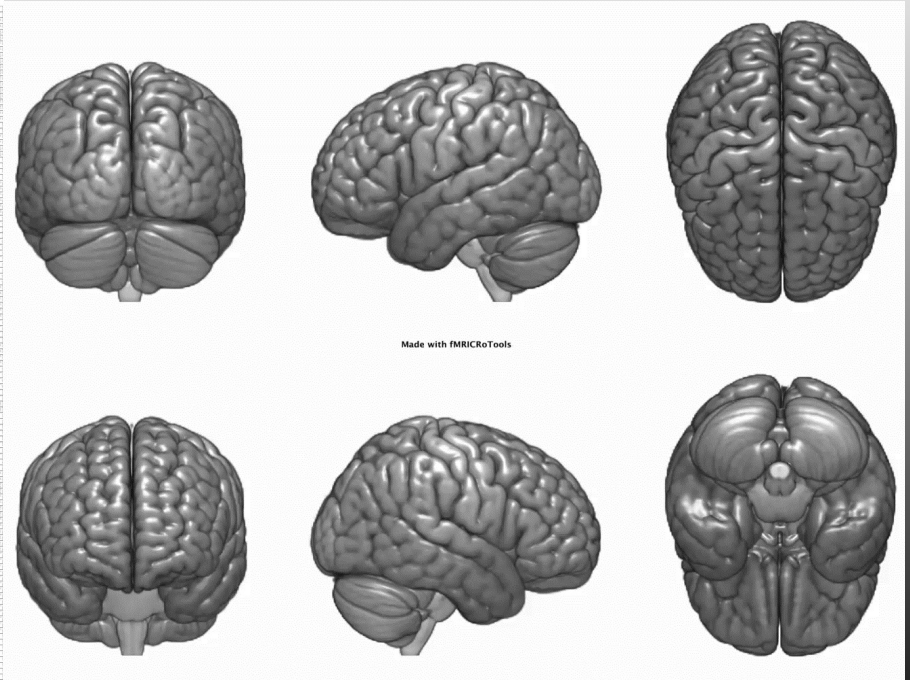
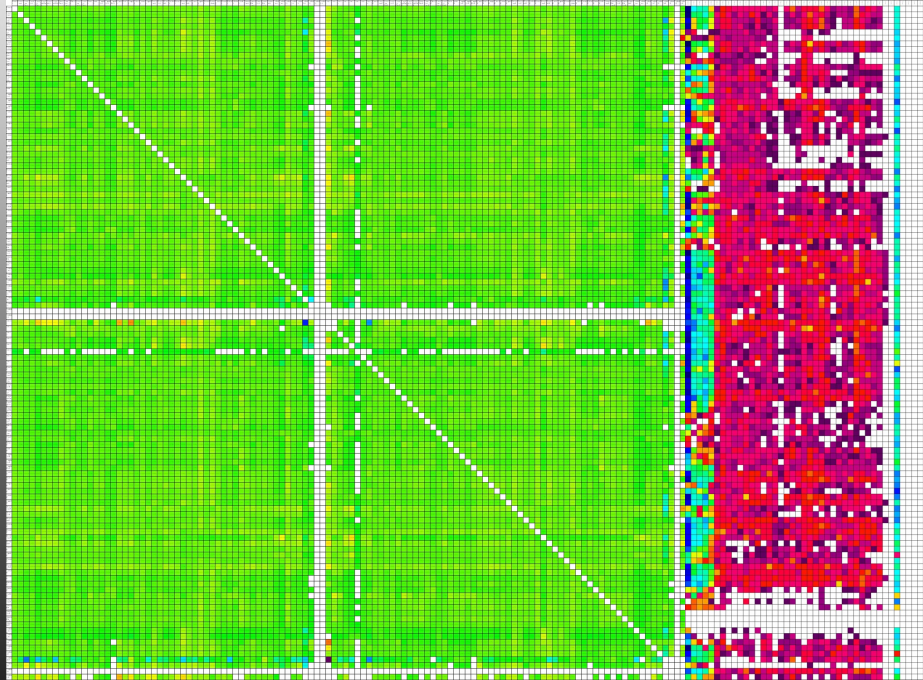
# Connectomique Structurelle



**BRAINANALYZE**

To Analyze the Brain in Function

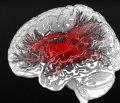
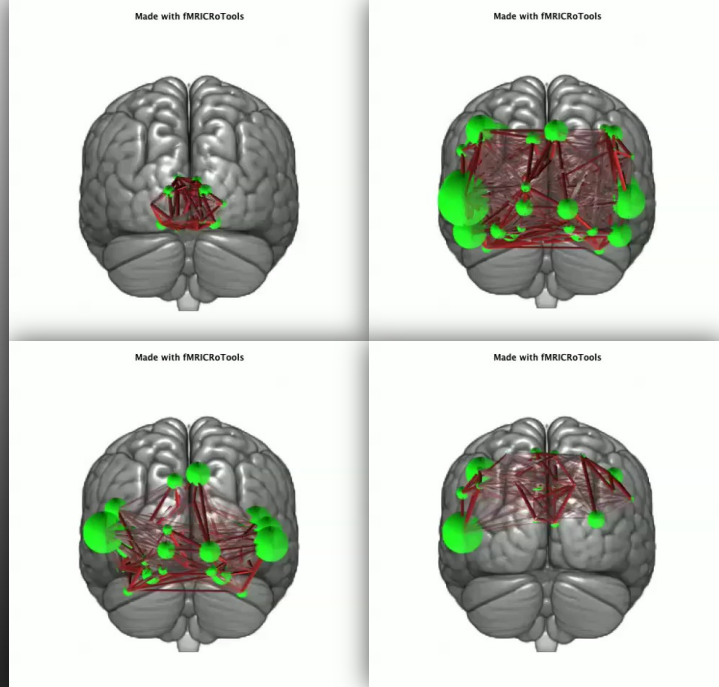
# Connectomique Fonctionnelle



**BRAINANALYZE**

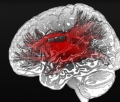
To Analyze the Brain in Function

# Connectomique Effective



BRAINANALYZE

# Intelligence Artificielle



**BRAINANALYZE**

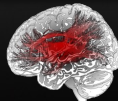
To Analyze the Brain in Function





The screenshot displays the BrainAnalyt software interface, which is divided into several main sections:

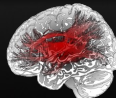
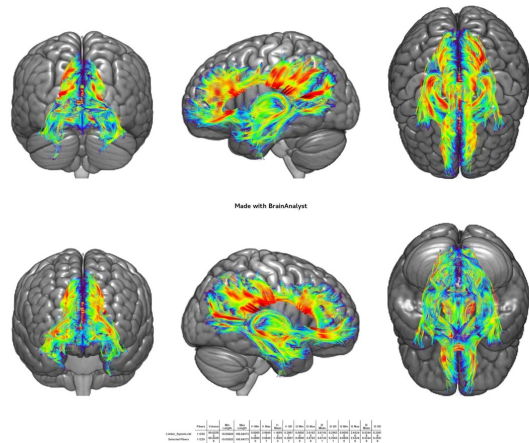
- Top Panel:** Contains navigation and tool icons for File I/O, Color/Contrast, Image Tools, MPR/3D Display, Overlays, ROI/VOI Drawing, and Virtual Reality.
- Left Panel:** Shows a 3D brain model with a color-coded overlay representing functional data. Below it is a line graph titled "FA Variations Through Location" with three data series (red, green, blue) plotted against a coordinate axis.
- Center Panel:** Displays a magnified view of a brain slice with red fiber-like structures. Below this is a "BrainAnalyt" logo and a "Voxel-Based Morphometry" section with "Single-Subject VBM" and "User's Functions" (1-6).
- Right Panel:** Shows a 3D brain model with a color-coded overlay. To its right is a "Connectors Data" panel listing various brain regions and bundles, such as "Postcentral\_L\_Bundle", "Pontine\_crossing\_tract", and "Finger\_movements".
- Bottom Panel:** Contains a "Database" section with "Connectopedia" and "Program Sequencer" tabs. It includes a "Series Processing" section with "VOIs, Reports, Filming" and a "Rendering Template" section with options for "Arteries", "Brain Ghost", "Connectors", "Extracted Cortex", "Veins", and "Virtual Dissection".



# BRAINANALYZE

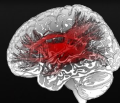
To Analyze the Brain in Function

# Connectomique Structurelle



**BRAINANALYZE**

To Analyze the Brain in Function



**BRAINANALYZE**

To Analyze the Brain in Function

BrainAnalyze, 25 rue du Maréchal Foch, 78000 Versailles, France



+33 1 39511522



contact@brainanalyze.com

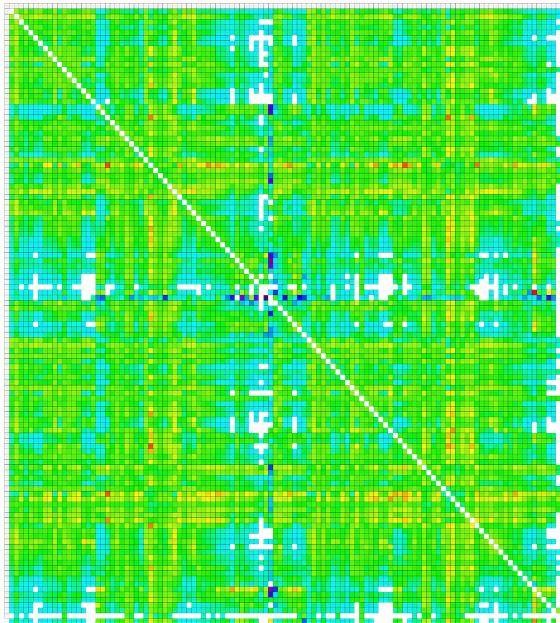
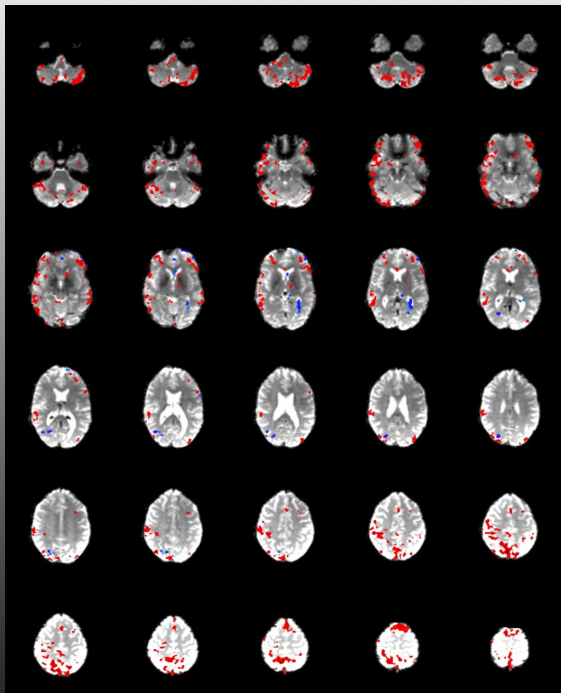


<https://brainanalyze.com>



@BrainAnalyze

# Connectomique Fonctionnelle



Broca Areas BA 6, 44, 45, 46, 47:

Broca L [voxels, cm3, min, max, mean, sd]:  
67, 0.536, -0.47154, 0.49268, 0.39071, 0.18357

Broca R [voxels, cm3, min, max, mean, sd]:  
9, 0.072, 0.40020, 0.49771, 0.43282, 0.03492

Broca Lateralization (L-R)/(L+R): 0.7631579041 (Left +++)

Broca Weighted Lateralization (rL\*vL-rR\*vR)/(rL\*vL+rR\*vR): 0.7409344912 (Left +++)

Wernicke Areas BA 20, 21, 22, 37, 38, 39, 40, 41, 42:

Wernicke L [voxels, cm3, min, max, mean, sd]:

4, 0.032, 0.40692, 0.41087, 0.40896, 0.00180

Wernicke R [voxels, cm3, min, max, mean, sd]:  
40, 0.320, 0.40042, 0.47887, 0.42405, 0.02192

Wernicke Lateralization (L-R)/(L+R): -0.8181818128 (Right +++)

Wernicke Weighted Lateralization (rL\*vL-rR\*vR)/(rL\*vL+rR\*vR): -0.8240846395 (Right +++)

Insula BA 13, 14, 15, 16:

Insula L [voxels, cm3, min, max, mean, sd]:

0, 0.000, 0.00000, 0.00000, 0.00000, 0.00000

Insula R [voxels, cm3, min, max, mean, sd]:

0, 0.000, 0.00000, 0.00000, 0.00000, 0.00000

Insula Lateralization (L-R)/(L+R): Not enough activated voxels (>3 minimum)!

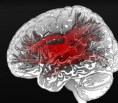
Insula Weighted Lateralization (rL\*vL-rR\*vR)/(rL\*vL+rR\*vR): Not enough activated voxels (>3 minimum)!

Geschwind Area BA 40:

Geschwind L (rL\*vL-rR\*vR)/(rL\*vL+rR\*vR):

0, 0.000, 0.00000, 0.00000, 0.00000, 0.00000

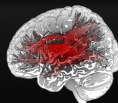
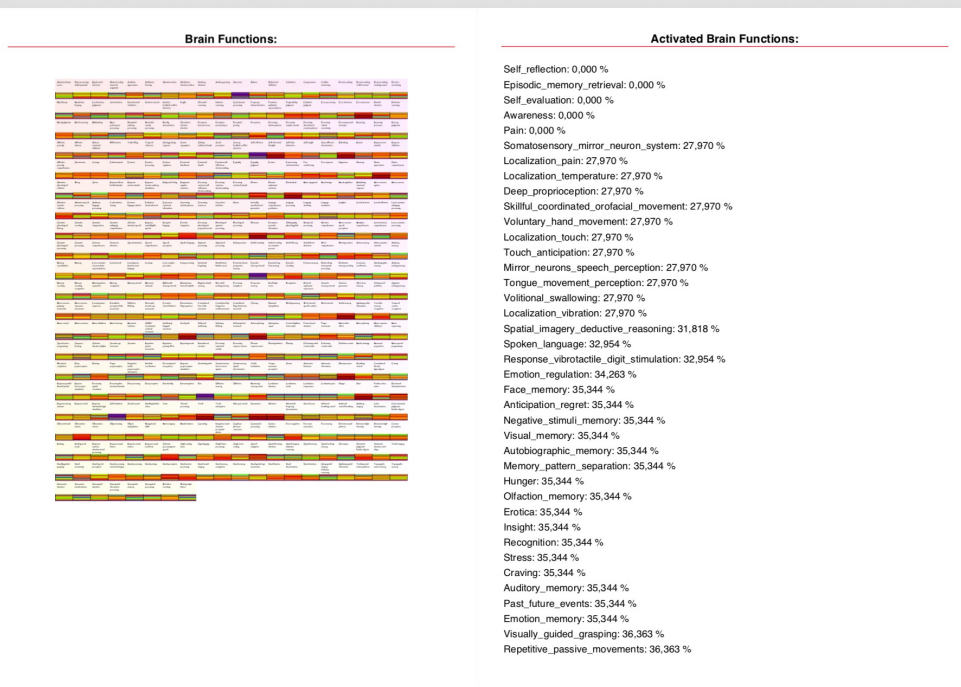
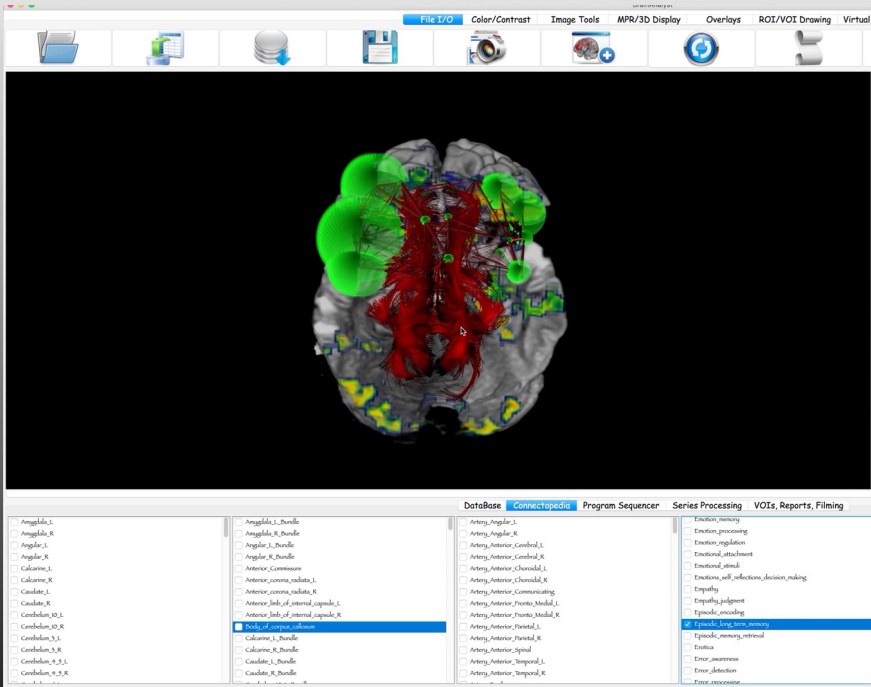
Geschwind R (rL\*vL-rR\*vR)/(rL\*vL+rR\*vR):



**BRAINANALYZE**

To Analyze the Brain in Function

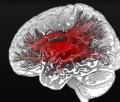
# Quantification de la Fonction Cérébrale



**BRAINANALYZE**

To Analyze the Brain in Function

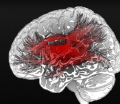
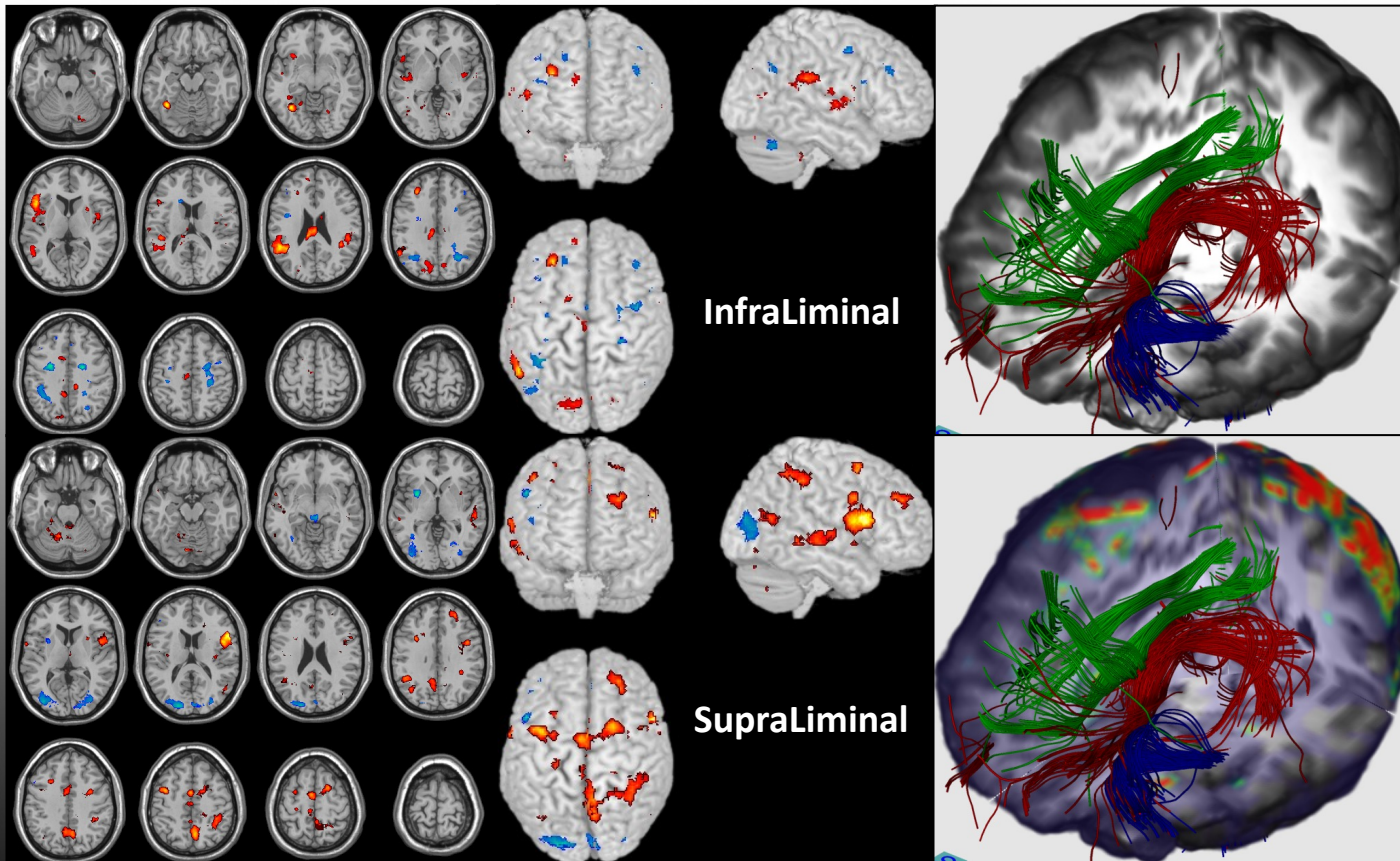
# Régulation émotionnelle : Les patients dépressifs



**BRAINANALYZE**

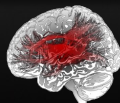
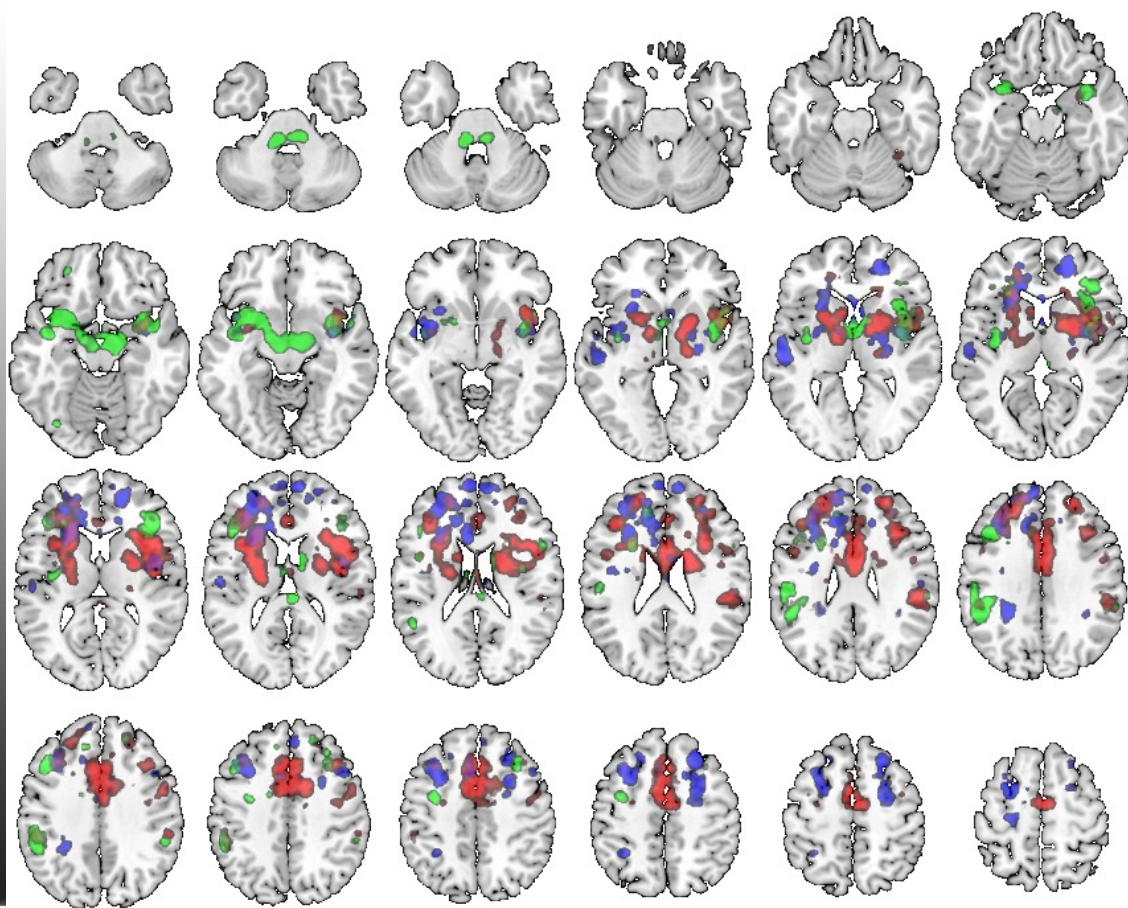
To Analyze the Brain in Function





**BRAINANALYZE**

To Analyze the Brain in Function



**BRAINANALYZE**

To Analyze the Brain in Function



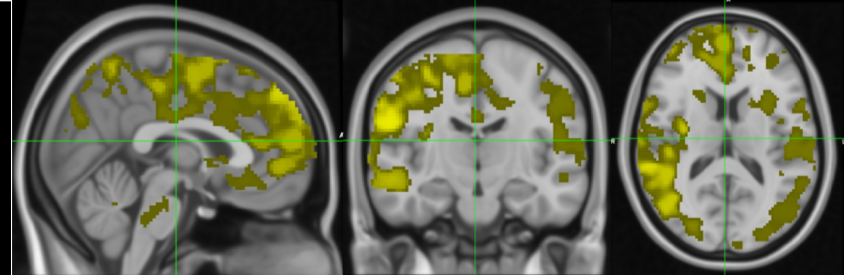
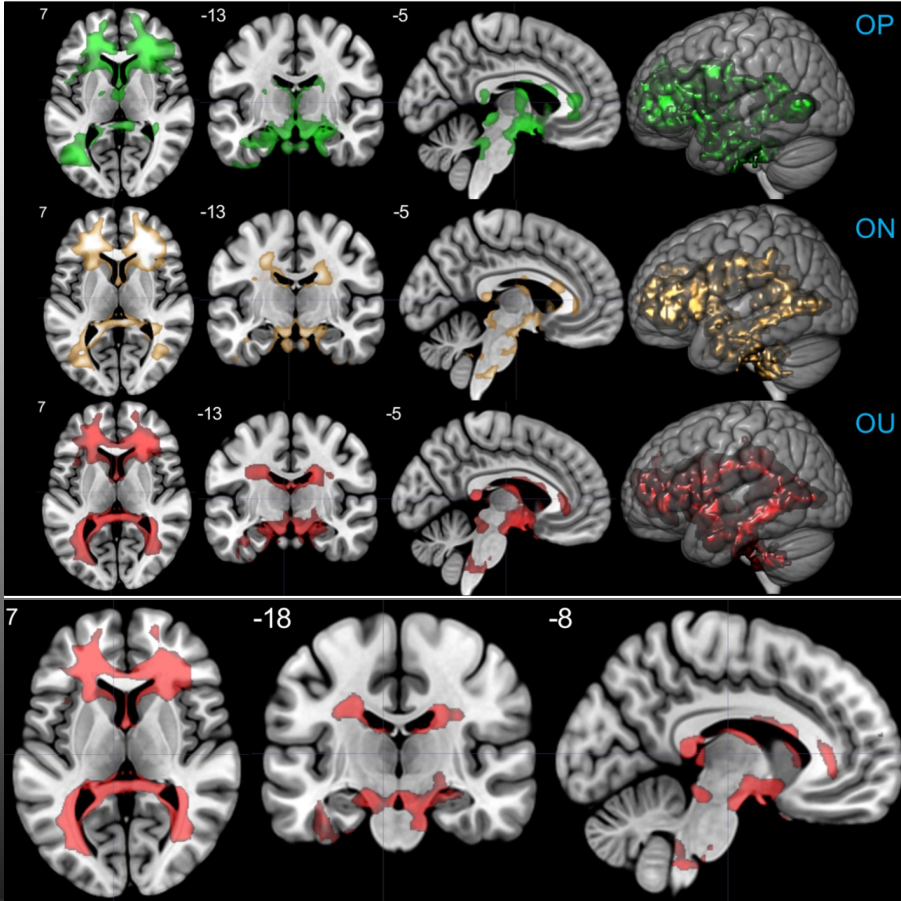
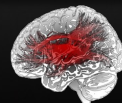
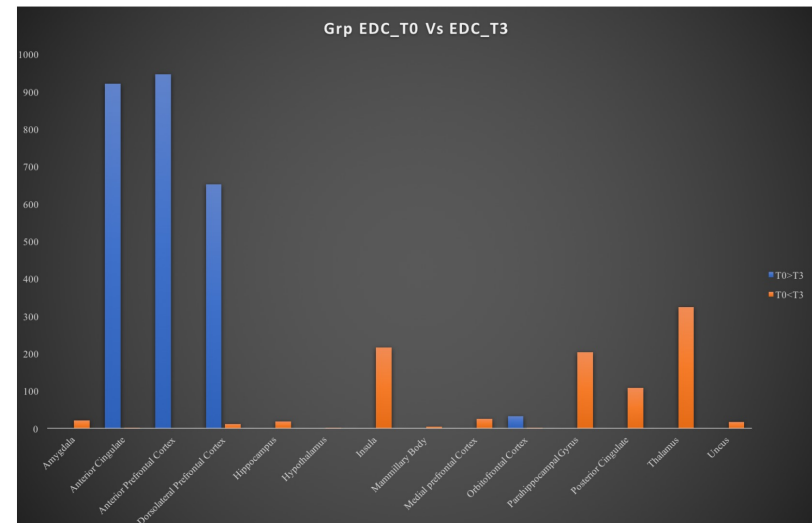
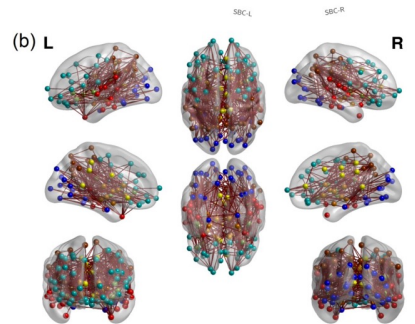
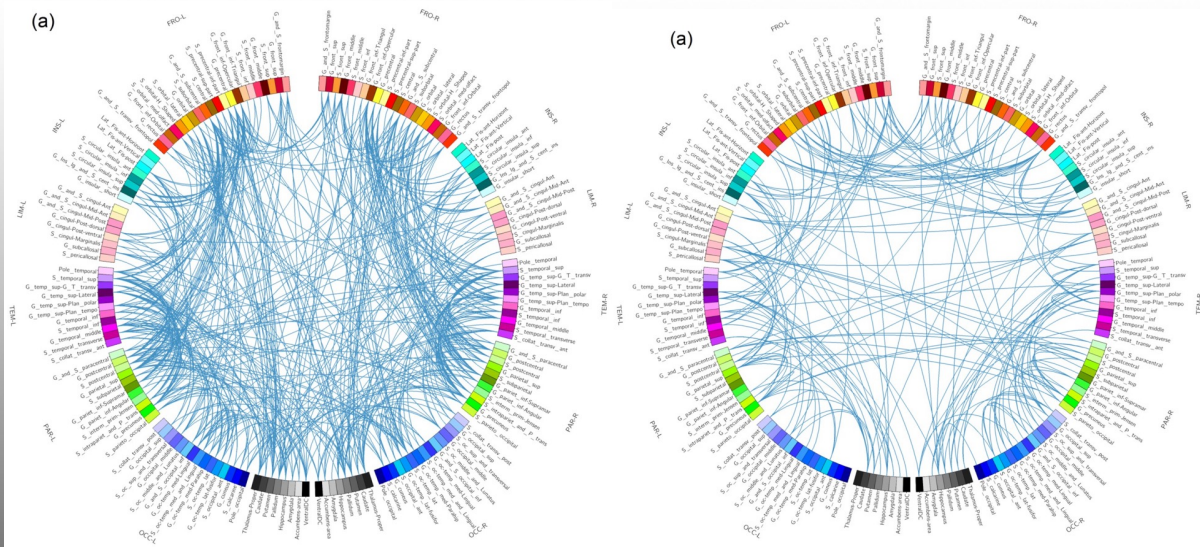


Fig. 4.8 Les régions cérébrales mise en évidence par le contraste  $ON > OU$  chez les deux groupes,  $P_{val} < 0.05$

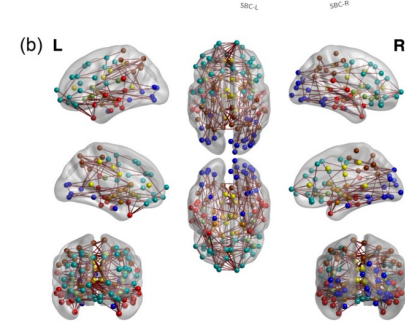


**BRAINANALYZE**

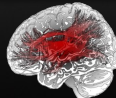
To Analyze the Brain in Function



- Cortex cingulaire
- Cortex frontal
- Substancie grise sous corticale
- Cortex pariétal
- Cortex temporal
- Cortex occipital
- Cortex insulaire

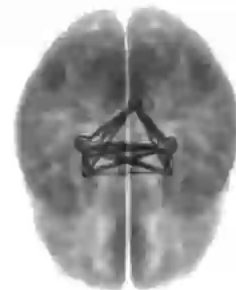
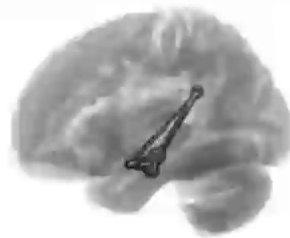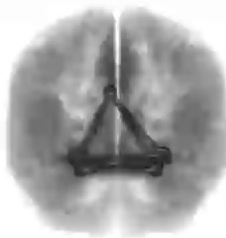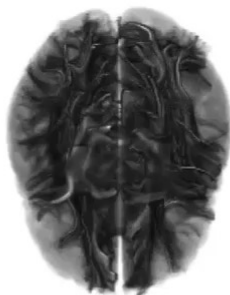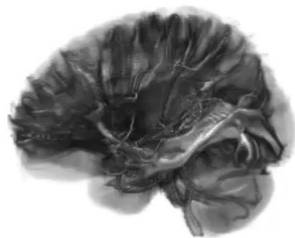
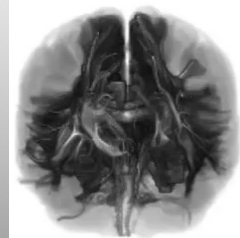


- Cortex cingulaire
- Cortex frontal
- Substancie grise sous corticale
- Cortex pariétal
- Cortex temporal
- Cortex occipital
- Cortex insulaire



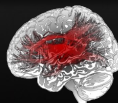
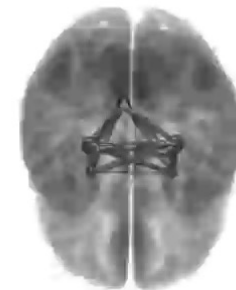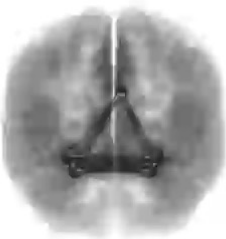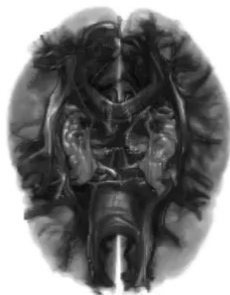
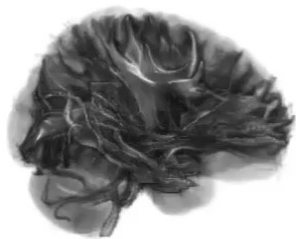
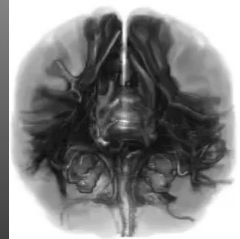
# BRAINANALYZE

To Analyze the Brain in Function



Made with Connectopia

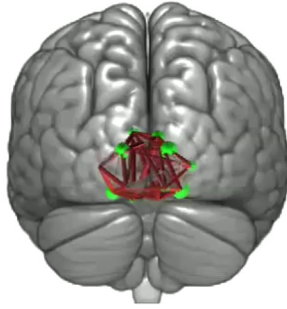
Made with Connectopia



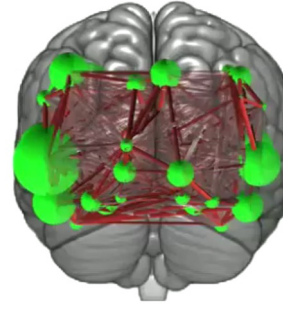
**BRAINANALYZE**

To Analyze the Brain in Function

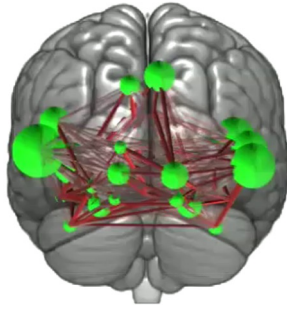
Made with fMRICRoTools



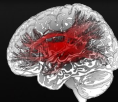
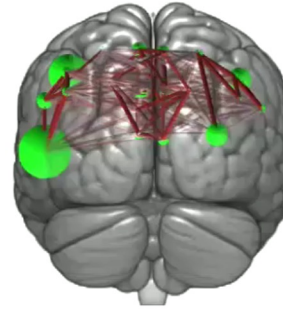
Made with fMRICRoTools



Made with fMRICRoTools

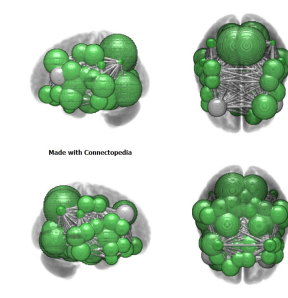
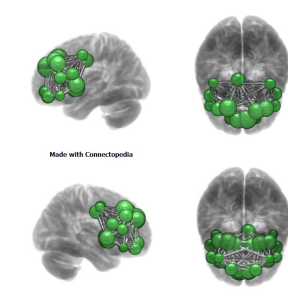
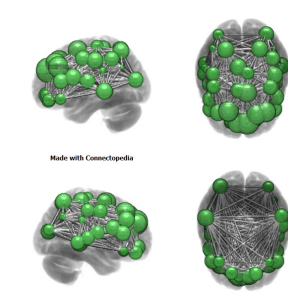
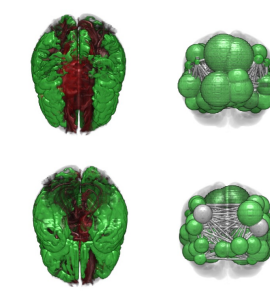
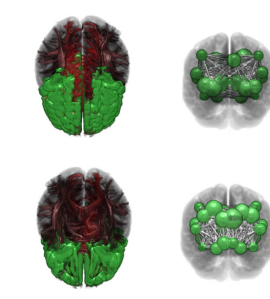
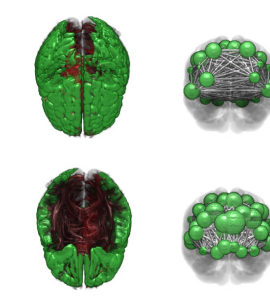
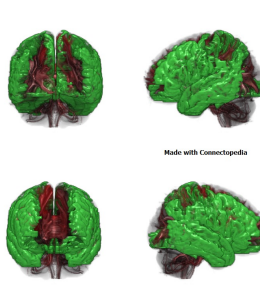
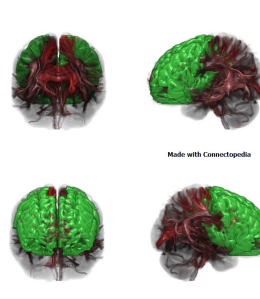
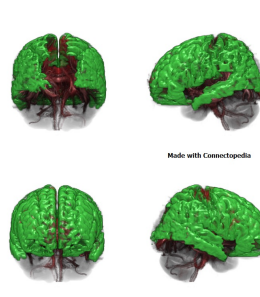
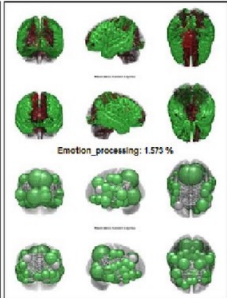
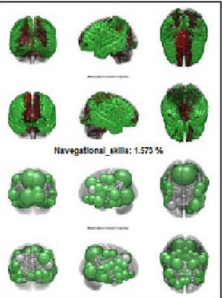
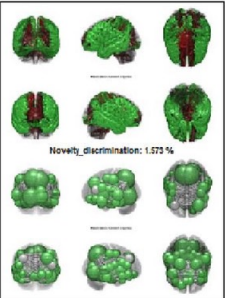
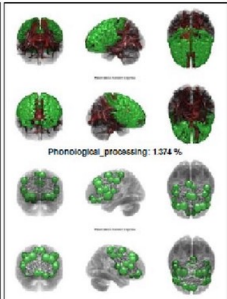
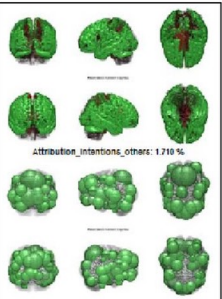
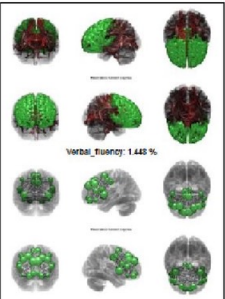
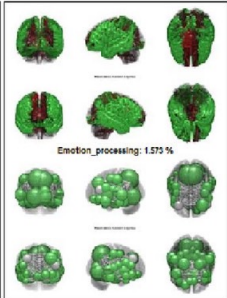
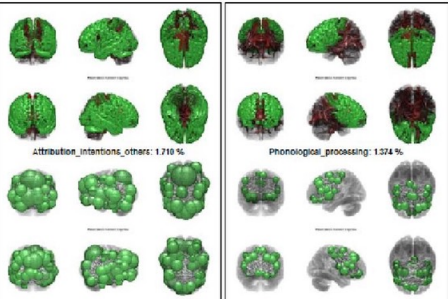
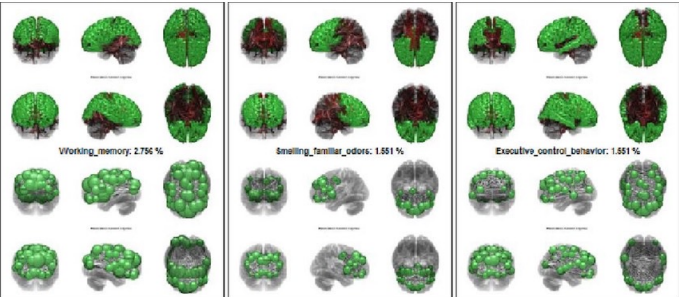


Made with fMRICRoTools



**BRAINANALYZE**

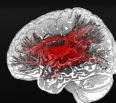
To Analyze the Brain in Function



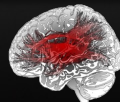
*Executive Control  
Behavior: 1,551 %*

*Smelling Familiar  
Odor: 1,551 %*

*Emotion  
Processing:  
1,573 %*



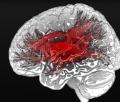
**BRAINANALYZE**  
To Analyze the Brain in Function



# BRAINANALYZE

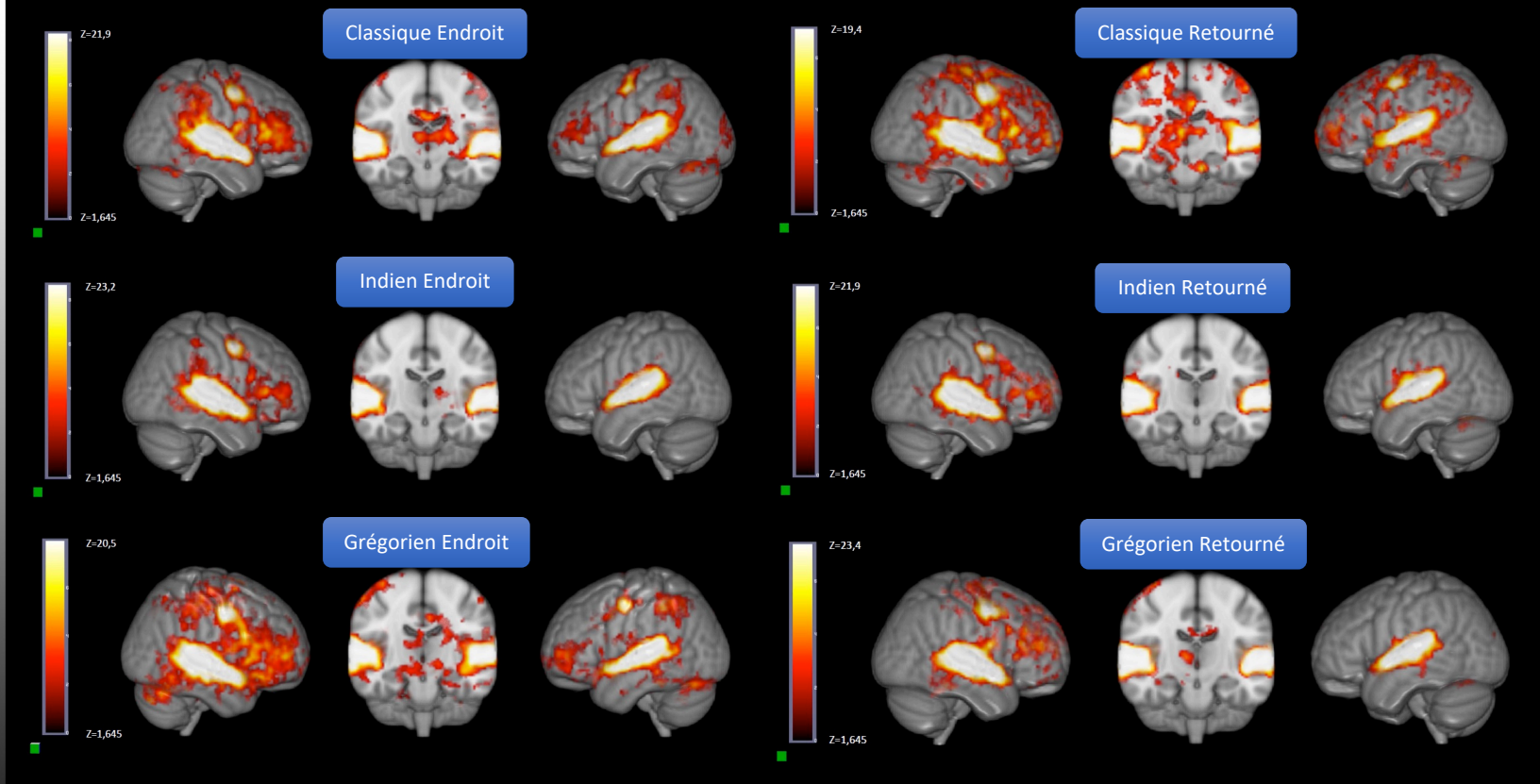
To Analyze the Brain in Function

# Effet de la musique sur le cerveau

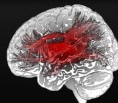


**BRAINANALYZE**

To Analyze the Brain in Function



*Etude comparative des réseaux neuronaux intégratifs mis en œuvres lors de stimulations auditives modales et tonales en IRM fonctionnelle cérébrale de tenseur de diffusion et d'activation. J.B. Billaud, Master M2*

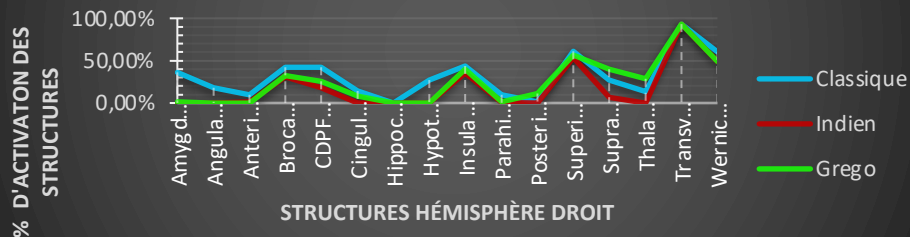


**BRAINANALYZE**

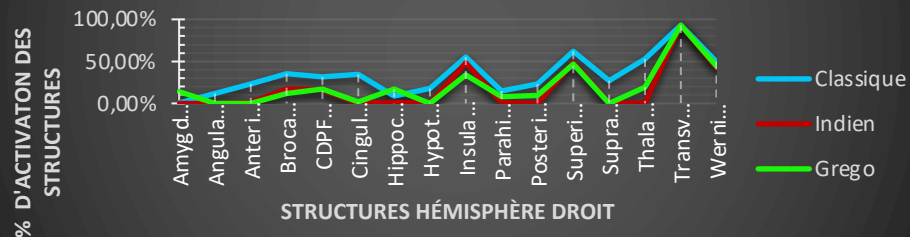
To Analyze the Brain in Function



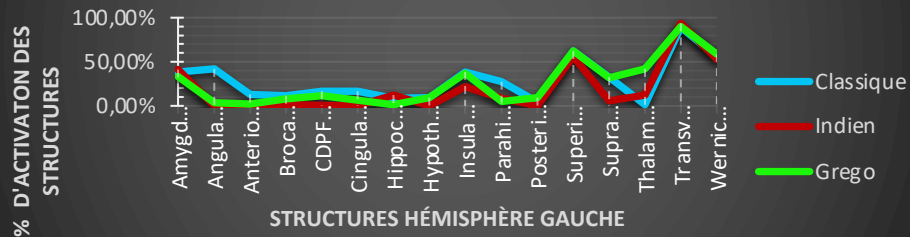
## Variation de l'activation dans les structures d'intérêt | Sens de lecture à l'endroit



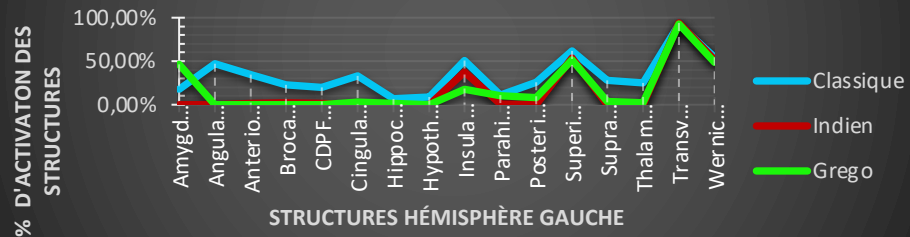
## Variation de l'activation dans les structures d'intérêt | Sens de lecture inversé



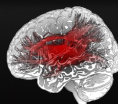
## Variation de l'activation dans les structures d'intérêt | Sens de lecture à l'endroit



## Variation de l'activation dans les structures d'intérêt | Sens de lecture inversé



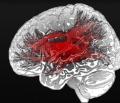
Etude comparative des réseaux neuronaux intégratifs mis en œuvre lors de stimulations auditives modales et tonales en IRM fonctionnelle cérébrale de tenseur de diffusion et d'activation. J.B. Billaud, Master M2



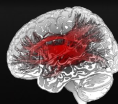
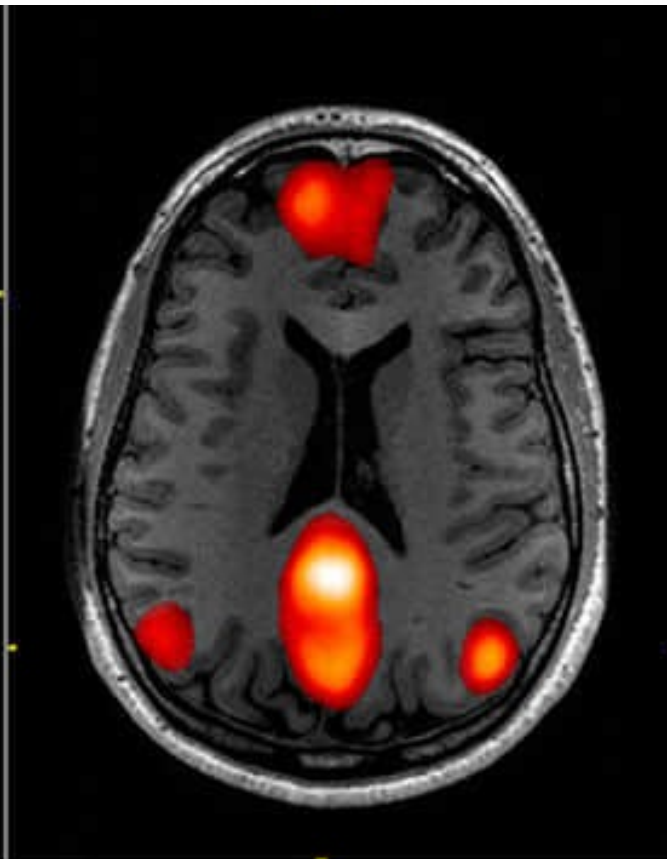
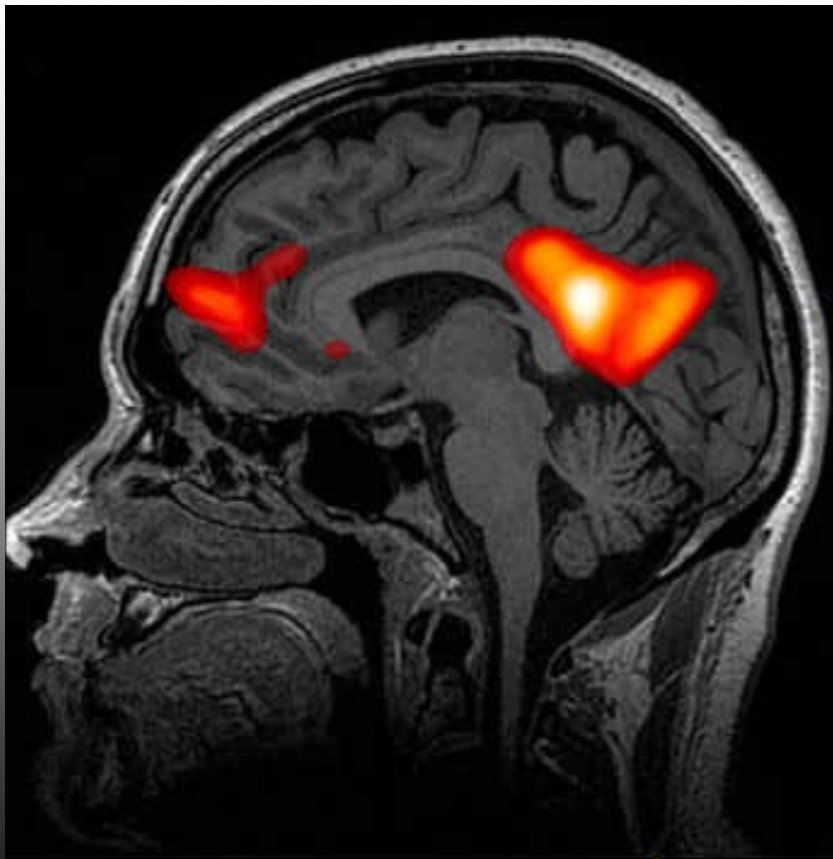
**BRAINANALYZE**

To Analyze the Brain in Function

# Effet de la méditation sur le cerveau

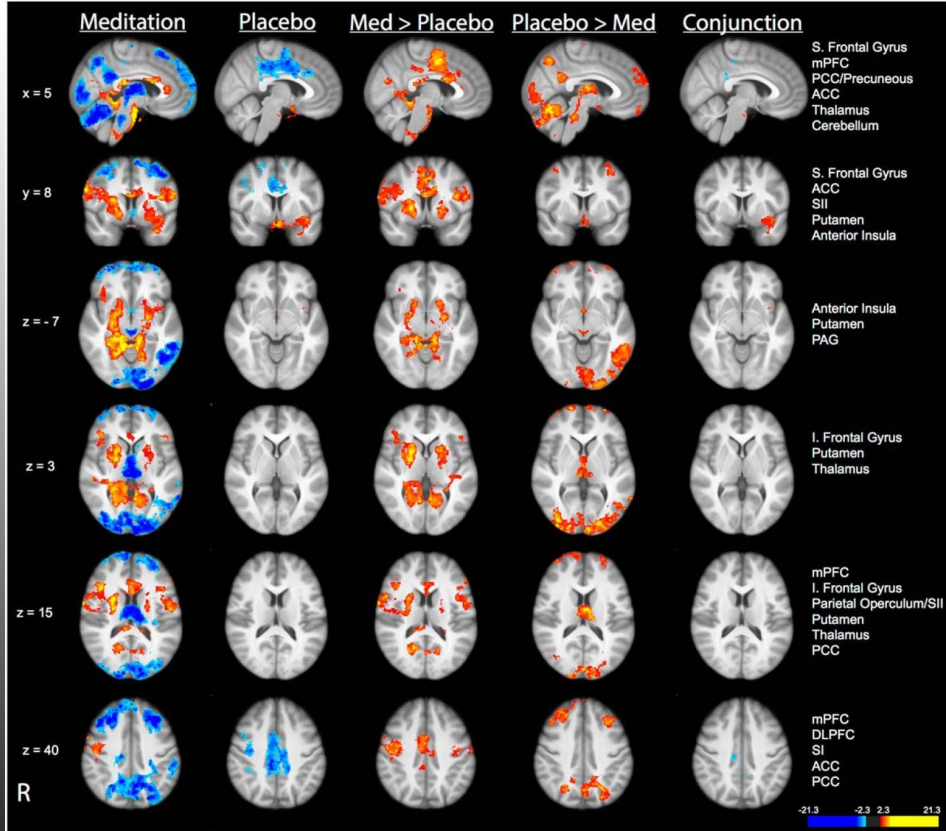


To Analyze the Brain in Motion  
**BRAINANALYZE**

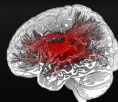


**BRAINANALYZE**

To Analyze the Brain in Function

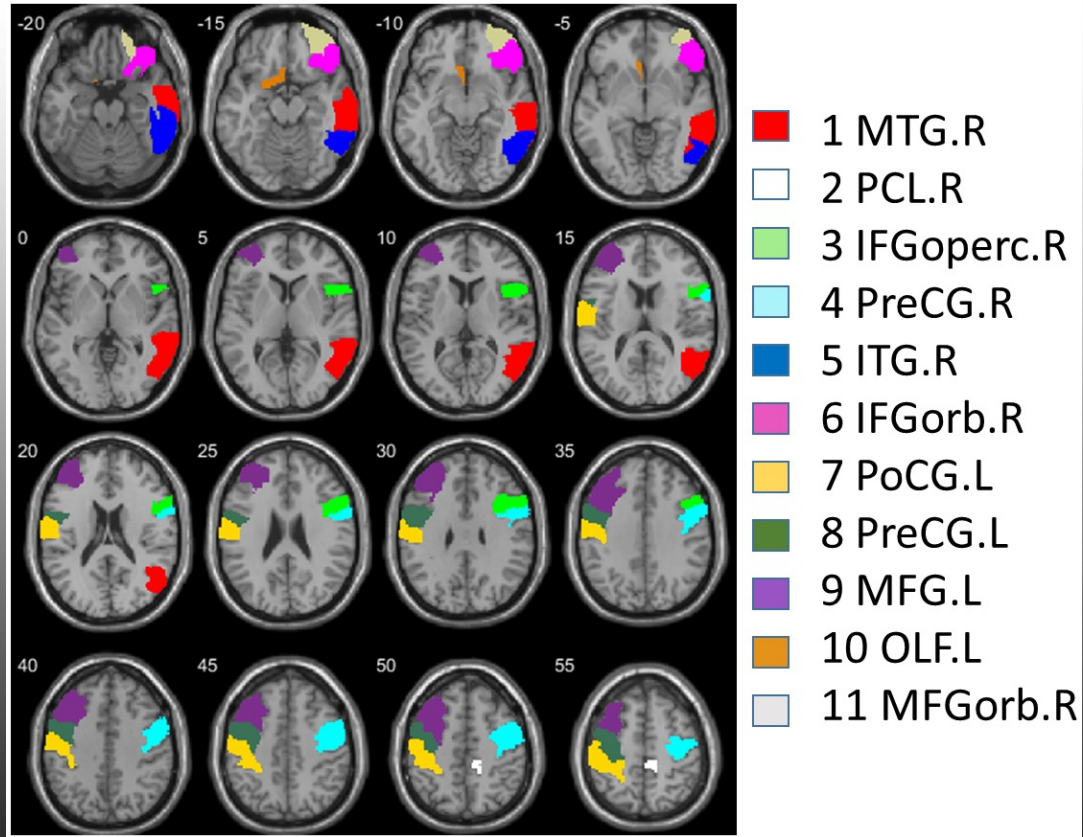


Mindfulness Meditation-Based Pain Relief Employs Different Neural Mechanisms Than Placebo and Sham Mindfulness Meditation-Induced Analgesia. Fadel Zeidan, Nichole M. Emerson, Suzan R. Farris, Jenna N. Ray, Youngkyoo Jung, John G. McHaffie and Robert C. Coghill. *Journal of Neuroscience* 18 November 2015, 35 (46) 15307-15325

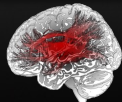


**BRAINANALYZE**

To Analyze the Brain in Function

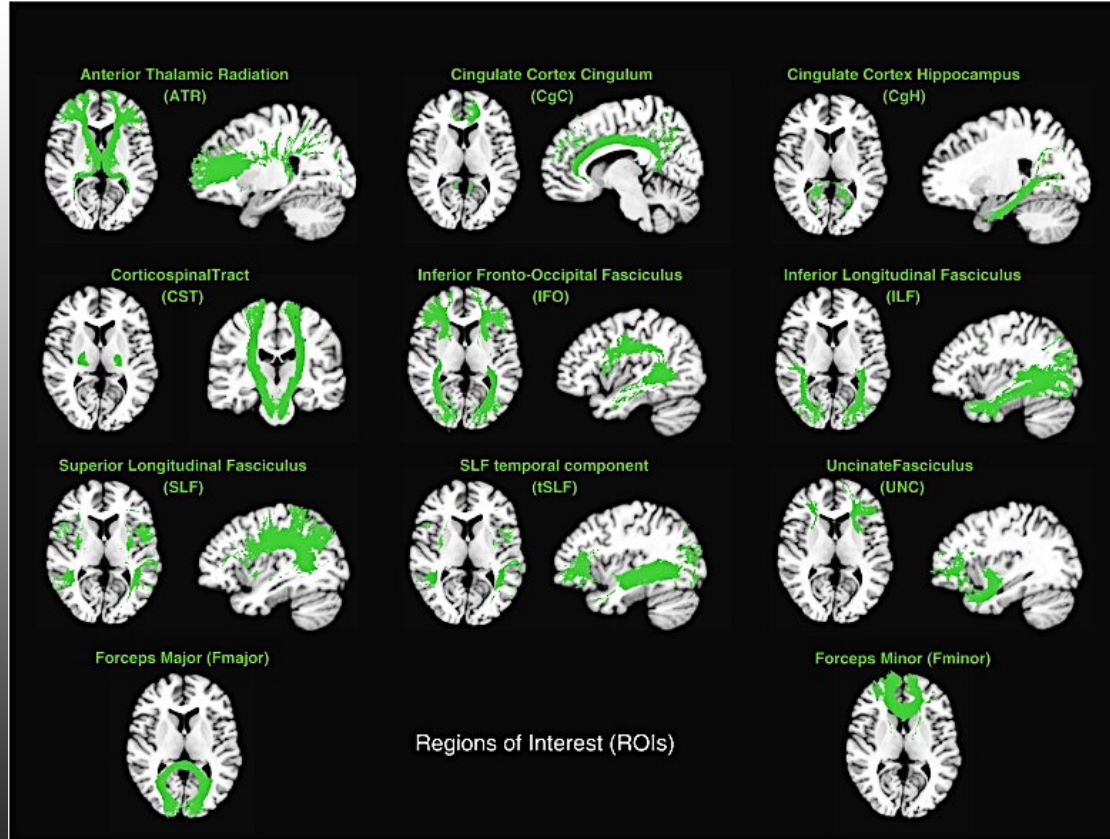


Larger whole brain grey matter associated with long-term Sahaja Yoga Meditation: A detailed area by area comparison. Hernandez S, Dorta R. Suero J., Barros-Loscertales A., Gonzalez-Mora J., Rubia K. Plos One, 2020, Dec. 28



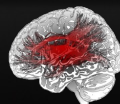
**BRAINANALYZE**

To Analyze the Brain in Function



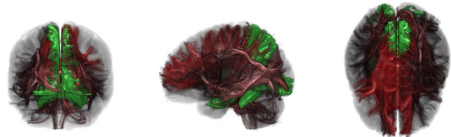
Enhanced brain connectivity in long-term meditation practitioners

Luders E., Clark K., Narr K., Toga A. Neuroimage Vol 57, Iss 4, Aug 2011, 1308-1316

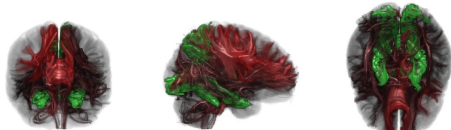


**BRAINANALYZE**

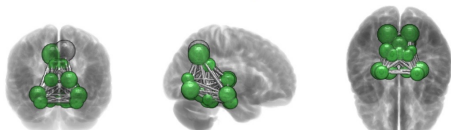
To Analyze the Brain in Function



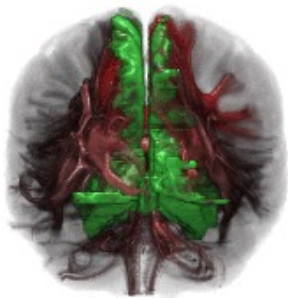
Made with Connectopedia



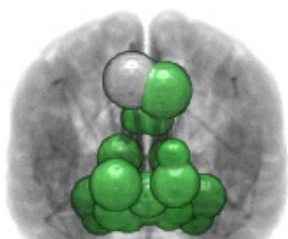
Made with Connectopedia



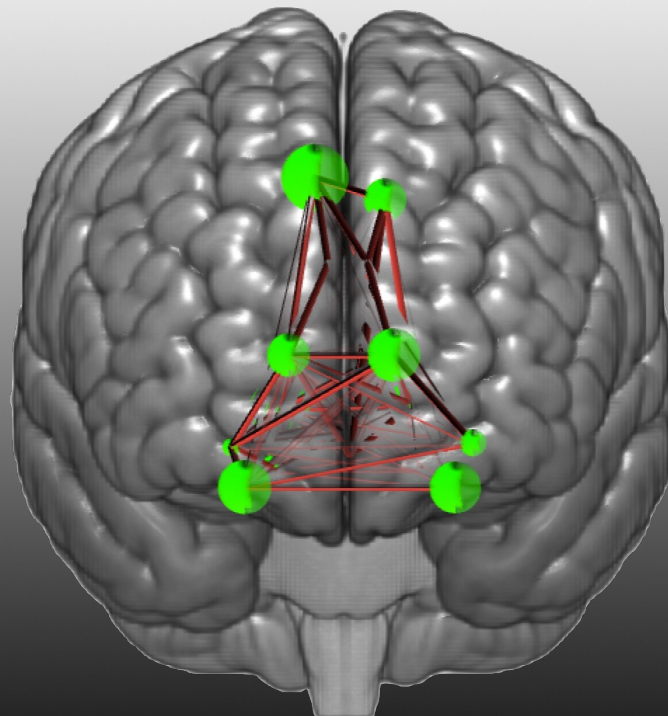
### Made with Connectopedia



### Made with Connectopedia



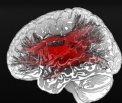
# Insight



**Gray Matter Structures:**  
 Callotus\_Ri Cerebellum\_S\_Li Cerebellum\_S\_Ri Cerebellum\_S\_S\_Li Cerebellum\_S\_S\_Ri Cingulum\_Post\_Li Cingulum\_Post\_Ri  
 Hippocampus\_Li Hippocampus\_Ri Lingual\_Li Lingual\_Ri Foveal Hippocampal\_Li Foveal Hippocampal\_Ri Fusiform\_Li Fusiform\_Ri  
 Thalamus\_Li Thalamus\_Ri Vermis\_3i Vermis\_4\_Si

**White Matter Bundles:**  
 Anterior\_Commissure Anterior\_corona\_radiata\_Li Anterior\_corona\_radiata\_Ri Anterior\_lab\_of\_internal\_capsule\_Li  
 Anterior\_lab\_of\_internal\_capsule\_Ri Body\_of\_corpus\_callosum Cerebellar\_peduncle\_Li Cerebellar\_peduncle\_Ri  
 Cingulum\_(cingulate\_gyrus)\_Li Cingulum\_(cingulate\_gyrus)\_Ri Cingulum\_(hippocampus)\_Li Cingulum\_(hippocampus)\_Ri Corpus\_Callosum  
 Corticospinal\_tract\_Li Corticospinal\_tract\_Ri External\_capsule\_Li Fornix Inferior\_Fronto\_Occipital\_Li Inferior\_Fronto\_Occipital\_Ri  
 Inferior\_Lingual\_Li Inferior\_Lingual\_Ri Limbic\_System Medial Lemniscus\_Li Medial Lemniscus\_Ri Middle\_cerebellar\_peduncle  
 Frontier\_crossing\_tract Posterior\_Commissure Posterior\_corona\_radiata\_Li Posterior\_corona\_radiata\_Ri  
 Posterior\_lab\_of\_internal\_capsule\_Li Posterior\_lab\_of\_internal\_capsule\_Ri Posterior\_thalamic\_radiation\_Li  
 Posterior\_thalamic\_radiation\_Ri Retrolenticular\_part\_of\_internal\_capsule\_Li Retrolenticular\_part\_of\_internal\_capsule\_Ri  
 Sagittal\_stratum\_Li Sagittal\_stratum\_Ri Spino\_Thalamic\_Li Spino\_Thalamic\_Ri Splenium\_of\_corpus\_callosum Stria\_terminalis\_Li  
 Stria\_terminalis\_Ri Superior\_cerebellar\_peduncle\_Li Superior\_cerebellar\_peduncle\_Ri Superior\_corona\_radiata\_Li  
 Superior\_corona\_radiata\_Ri Superior\_fronto-occipital\_fasciculus\_Li Tapetum\_Li Tapetum\_Ri Uncinate\_fasciculus\_Ri

**Brodmann Areas:**  
 27

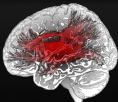
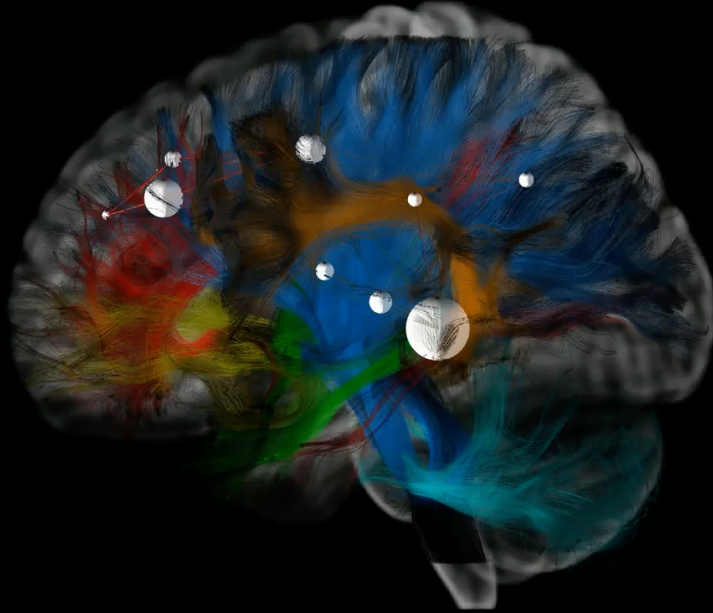


## BRAINANALYZE

To Analyze the Brain in Function

Made with BrainAnalyst

# Awakening



**BRAINANALYZE**

To Analyze the Brain in Function

BrainAnalyze, 25 rue du Maréchal Foch, 78000 Versailles, France



+33 1 39511522



contact@brainanalyze.com



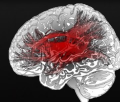
<https://brainanalyze.com>



@BrainAnalyze



# Conclusions



**BRAINANALYZE**

To Analyze the Brain in Function



